

Radiography of OS Calcaneus with Spur Study Formation at Columbia Asia Hospital Medan

Juliana Sidauruk¹, Djamiandar Simamora¹

¹Akademi Teknik Radiodiagnostik Dan Radioterapi Yayasan Sinar Amal Bhakti Medan, Indonesia

Article Info

Article history:

Received November 27, 2023

Revised December 01, 2023

Accepted December 23, 2023

Corresponding Author:

Juliana Sidauruk
Akademi Teknik
Radiodiagnostik Dan
Radioterapi Yayasan Sinar
Amal Bhakti Medan, Indonesia
Email:
julianasidauruk75@gmail.com

ABSTRACT

Radiographic examination of the calcaneus bone using X-rays can clearly determine the location of the spur formation. The aim of this study was to determine the procedure for carrying out Os Calcaneus radiography with suspected spur formation at Columbia Asia Hospital, Medan. The type of examination used is descriptive qualitative. Data collection techniques are based on the results of literature reviews, interviews, observations and documentation. This examination was carried out at Columbia Asia Hospital Medan, in January 2020, using a General X-ray unit x-ray, 18 cm x 24 cm cassette, with image processing using Computed Radiography. The results of the research obtained radiographic images of the calcaneus bone with greater detail and sharpness, so that it could show spur formation on the calcaneus bone. To show the anatomical picture and pathological abnormalities in the Os Calcaneus with suspected spur formation, it can be done using Axial and Lateral projections.

Keywords:

Os Calcaneus, Spur Formation, Computed Radiography (CR)

This article is licensed under a [Creative Commons Attribution 4.0 International License](https://creativecommons.org/licenses/by-sa/4.0/).



1. INTRODUCTION

The ossa pedis is the bony part of the lower extremity or lower limb. The foot bones (Ossa pedis) consist of 26 bones, namely 14 phalanx bones, 5 metatarsal bones and 7 tarsal bones. Foot bones are generally almost similar to hand bones but differ in structure [1]. The ossa pedis or foot bones function for walking and support body weight. The calcaneus bone is part of the ossa pedis [2].

The calcaneus bone or heel bone is a box-shaped, irregular and elongated bone with a long axis that is generally oriented along the midline of the pedis, but in the anterior it deviates laterally from the midline. The calcaneus projects behind the talocrural joint to form the bony framework of the calcanea region. The posterior surface of the calcanea region is round and divided into upper, middle and lower parts [3].

Spur is a bone growth that occurs due to damage to the joint, thus forming bone spurs (Laksman, 2005). If a spur occurs on the calcaneus bone, it will be very difficult for the sufferer to carry out activities and will feel pain. To determine whether there is a spur or not, a radiographic examination is carried out using X-rays. With the help of X-rays we can find out the location of the calcaneus spur [4]. Based on this, the author wants to study further about radiography of the calcaneus bone with the suspicion of spur formation in the form of a scientific paper with the title: Radiography Of The Calcaneus Os With The Suspect Of Spur Formation In Columbia Asia Hospital Medan

In radiographic examination of the calcaneus bone with suspected spur formation, several projections are carried out, namely axial and lateral. The aircraft used is a General X-ray Unit using a small focus of 100 mA, the image recording process uses Computer Radiography (CR) [5].

Based on the background of radiographic examination of the calcaneus bone with suspected spur formation, the problem formulation obtained is as follows: "How do I get an optimal radiographic image of the calcaneus bone with suspected spur formation?" [6].

Radiation Protection is a branch of science or engineering that studies human and environmental health problems and is related to providing protection to a person or group of people or their descendants against the possibility of harm to health due to exposure to radiation. The aim of radiation safety is to prevent dangerous deterministic effects and reduce the occurrence of stochastic effects as low as possible. The radiation protection program is intended to reduce the occurrence of radiation accidents to personnel, patients and the general public as low as possible. This radiation protection program aims to protect radiation workers and the general public from the dangers of radiation caused by the use of radioactive substances or other radiation sources.

Computer Radiography is an image digitization process that uses sheets or photostimulable plates for image data acquisition. Then digital data in the form of signals is captured by the photo multiplier tube (PMT), after which the light is doubled and its intensity is strengthened. The data is converted into electrical signals which will be converted into digital data by an analog digital converter (ADC). Conventional radiography uses cassettes, film and screen, while computed radiography only uses [7].

After leaving the image reader, the radiographic image will be displayed on the Computed Radiography monitor. The radiographer can change the reconstruction factors if he wants to see certain structures in the image. Images can be displayed on a monitor or printed onto radiographic film. If the image is displayed on the monitor, the user can check all the image features to the best advantage to visually adjust the image characteristics. After that, the image will be sent to the printer [8].

In the form of a special computer for medical imaging with a touch screen monitor. The imaging console is equipped with various menus that support the editing and image processing process according to body anatomy, such as the condition of the images of body organs, bone condition and soft tissue condition. There is a menu that is very necessary in radiophotography techniques, namely that we can increase or reduce the density, sharpness, contrast and detail of the radiographic image obtained [9].

Pathology is the science that studies body structure and changes related to disease or injury (Sloane, 2003). Calcaneus spur begins with repeated injury at the site of attachment of the plantar aponeurosis to the calcaneus. This repeated injury will cause microscopic tears resulting in inflammation in the area. When a tear occurs, a new layer is formed (in the form of calcium deposits). Over time, this layer thickens, forming a spur on the heel which is tucked into the plantar fascia at the base of the heel bone [10].

Radiographic technique is a science that studies the procedures for photographing using x-rays to create optimal radiographic images and aims to establish a diagnosis [11]. Radiography of the calcaneus bone with suspected spur formation is an examination to show an optimal radiographic image so that it can provide good information from the x-ray image.

X-ray aircraft technique is how to use the X-ray aircraft to run the examination smoothly with optimal radiographic image results. An X-ray machine is one of the radiological installation equipment which has an important role in being able to produce X-rays and can provide an image of objects on the X-ray film after going through the washing process (Meredith, 1972). An X-ray aircraft is one of the most important pieces of equipment in carrying out radiodiagnostic examinations, whether the X-ray photo results are good or not cannot be separated from how the radiographer uses the aircraft. X-ray technique is part of the procedures for using the X-ray machine to ensure that the examination runs smoothly with optimal radiographic results [12].

Radiation Protection is a branch of science or engineering that studies human and environmental health problems and is related to providing protection to a person or group of people or their descendants against the possibility of harm to health due to exposure to radiation. The aim of radiation safety is to prevent dangerous deterministic effects and reduce the occurrence of stochastic effects as low as possible. The radiation protection program is intended to reduce the occurrence of radiation accidents to personnel, patients and the general public as low as possible [13]. This radiation protection program aims to protect radiation workers and the general public from the dangers of radiation caused by the use of radioactive substances or other radiation sources [14].

Computer Radiography is an image digitization process that uses sheets or photostimulable plates for image data acquisition. Then digital data in the form of signals is captured by the photo multiplier tube (PMT), after which the light is doubled and its intensity is strengthened. The data is converted into electrical signals which will be converted into digital data by an analog digital converter (ADC). Conventional radiography uses cassettes, film and screen, while computed radiography only uses imaging plate to take radiographic images. Even though the imaging plate physically looks like it uses the same screen as conventional radiography, the imaging plate has a very different function. Because the imaging plate only functions to store signals into a photo stimulable phosphor (PSP) and then convey image information in the form of digital data [15].

The image reader functions as a reader and processes images obtained from the image plate. The larger the memory capacity, the faster the time required for the image plate reading process, and it has a large storage capacity. The fastest time required to read an imaging plate on an image reader is 64 seconds. Apart from being a place in the reading process, the imaging reader also has a very important role in the image processing process, the imaging plate transportation system and the deletion of data on the imaging plate [16].

2. METHODS

Type of Research

Research on Os Calcaneus Radiography with suspected Spur Formation uses descriptive qualitative research. Data collection techniques are based on the results of observations and interviews. Qualitative research techniques are systematic scientific research into parts and phenomena and their relationships. Descriptive type research is one way of research by describing an object in accordance with existing reality [17].

Data Collection Techniques

To obtain correct and accurate data in preparing this scientific paper, the author used several methods as below:

1. Literature Review

To obtain theoretical support for the selected examination problem, the author read a lot of literature, both in the form of texts (theory), journals and directions from supervisors who helped the author in compiling a scientific paper about Os Calcaneus Radiography with the Spur Formation suspicion [18].

2. Observation.

The author observed the course of the radiographic examination of the calcaneus bone with suspected spur formation and made internal observations examination carried out at the Radiology Installation at Columbia Asia Hospital, Medan.

3. Documentation

By studying the results of radiographs of the calcaneus bone found during clinical practice, whether normal or abnormal, especially spurs.

4. Interview

By conducting interviews with patients regarding the disease they were suffering from, the author also consulted with radiographers and supervisors related to examinations and writing scientific papers.

Analysis of Results

The data analysis stage is the most important and decisive stage in a research. The data obtained is then analyzed with the aim of processing the data into information, so that the characteristics or properties of the data can be easily understood and are useful for answering problems related to research [19]. This analysis is carried out based on observations in the field or experience based on data obtained from interviews and observations and then compiled and conclusions drawn [20]. From the results of a radiographic examination of the calcaneus bone with suspected spur formation carried out at the Columbia Asia Hospital in Medan with lateral and axial projections. An image was obtained that was suitable and good for reading in making a diagnosis, because in this study the image recording process used CR (Computer Radiography) so that the image could be adjusted according to needs and could produce an image with optimal sharpness and detail [21].

3. RESULTS AND DISCUSSION

Results

When carrying out an examination, it is necessary to know the identity of the patient clearly, which is useful for identifying one patient from another patient so that there are no misunderstandings. In this chapter, the author can describe the identity of the patient before carrying out a radiography of the calcaneus bone with suspected spur formation at Columbia Asia Hospital Medan, with the patient data as follows:

Inspection Procedures

Patients come to Radiology with a letter of introduction from the doctor to carry out a radiographic examination, first the patient registers at the radiology counter and completes the administration. After that, the patient was told to go to the examination room to be photographed according to the doctor's request at Columbia Asia Hospital, Medan [22].

Patient Preparation

During a radiographic examination of the calcaneus bone with suspected spur formation, we do not make special preparations, what is done is that the patient is given an explanation about carrying out the procedure. inspection to be carried out. For example, all objects worn by the patient that could hinder the examination should be removed, such as ankle bracelets. Patients are advised not to move while the examination is in progress [23].

Tools Preparation

X-Ray Aircraft

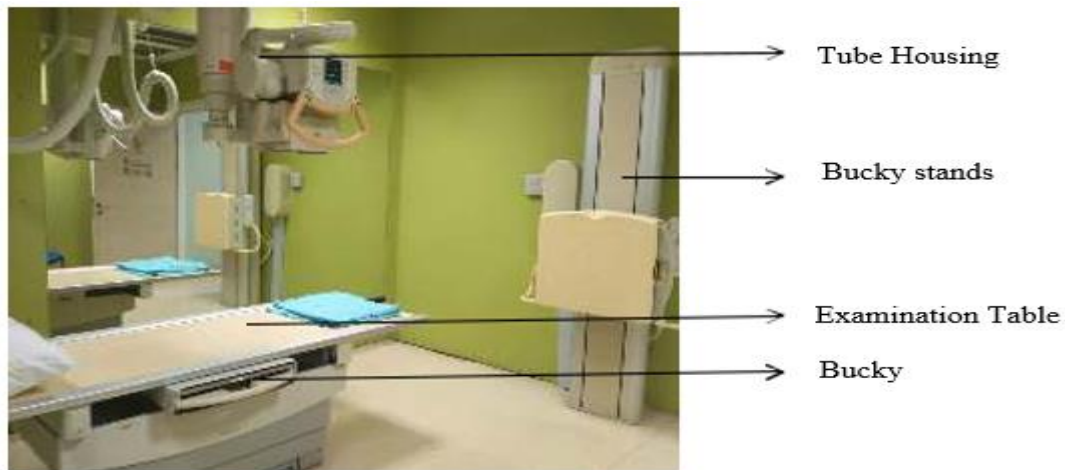


Figure 1.. General X-ray unit (Columbia Asia Hospital Medan)

The X-ray data used in examining the calcaneus os with suspected spur formation at Columbia Asia Hospital in Medan is:

Aircraft type : 9890-010-06522 SN11000043
 Bucky Diagnostics CS
 Aircraft brand : PHILIPS
 Incoming voltage :230V
 kV range : 150 kV
 mA range : 500 mA
 Frequency : 50-60 Hz

Inspection Equipment

1) Computer Radiography Cassette

The cassette used is a cassette measuring 18 cm x 24 cm which uses an imaging plate.

2) Computer Radiography Film

Also called laser imaging film. Laser imaging film is a type of single emulsion film measuring 18 cm x 24 cm.

3)Film processing using Computer Radiography.

5.Examination Techniques

The projection carried out by the author is adjusted to the problem limitations mentioned on the previous page, in carrying out spur formation with two projections, namely axial and lateral according to the patient's diagnostic needs.

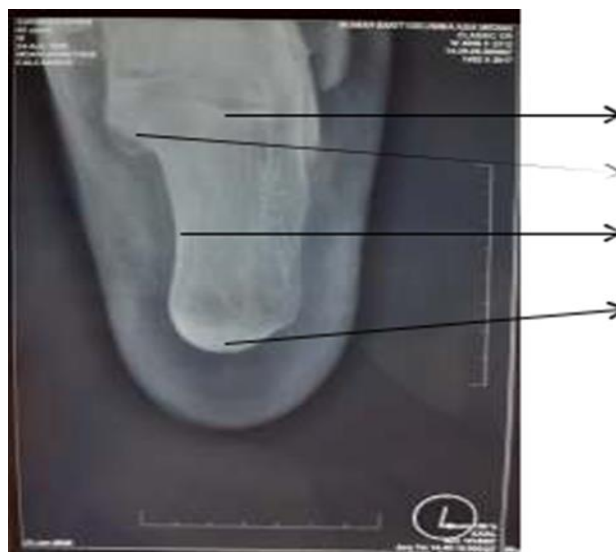


Figure 2. Radiograph of the Os Calcaneus with Axial Projection

Image criteria:

- a.An image of the calcaneus bone can be seen from the axial projection.
- b.The calcaneocuboid joint, sustentaculum tali, and tuberosity are visible [24].

- a. Sharpness is sufficient
- b. Enough details.

Lateral Projection

Patient position : The patient is supine on the examination table.
 Object position : Set and center the film directly on the calcaneus bone about 1-1 inches (2.5 – 4 cm) distal to the malleolus medial. Arrange the cassette so that the axis is long parallel to the plantar surface of the heel. Use of gonadal shields in patients.
 Ray Direction : Directed perpendicular to the center point of the os calcaneus [25].
 Cassette : 18 cm x 24 cm.
 Condition : 50 kV, and 5 mAs.

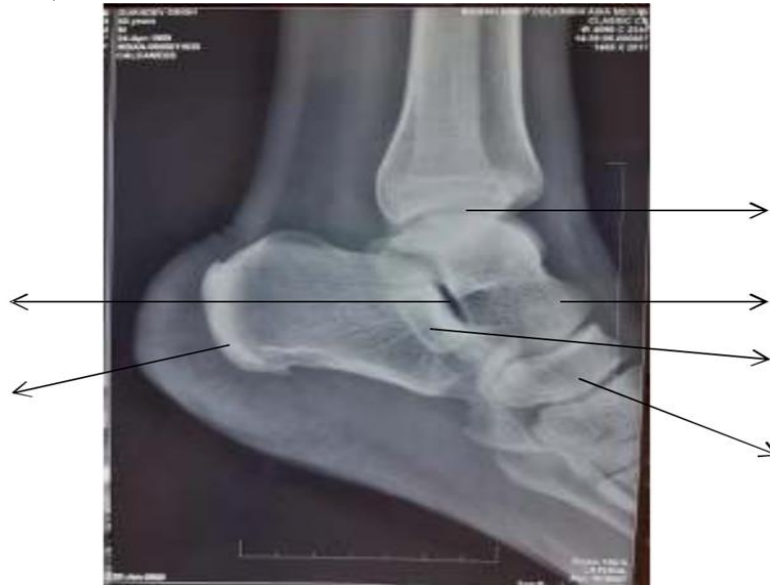

Figure 3. Radiograph of Os Calcaneus with Lateral Projection

Image criteria:

- a. The overall picture of the calcaneus bone is visible.
 - b. A picture of the sinus tarsi is visible.
 - c. A picture of the tibiotalar joint is visible.
 - d. Images of the talus, sustentaculum tali, and navicular are visible.
- Image evaluation:
- a. Sharpness is sufficient
 - b. Enough details

Expertise Results

The results of the expertise that we got at Columbia Asia Hospital in Medan were about the Os Calcaneus examination technique with the Spur Formation suspicion which was read by Dr. Buter Samin, Sp. Rad. Description of Examination Results (Os Calcaneus):

- a. Bone position and structure are good
- b. Looks like spurs
- c. Common joint gaps

Conclusion: Calcaneus Spur

Discussion

1. Formulation of the problem

After carrying out a radiographic examination of the calcaneus bone with suspected spur formation at Columbia Asia Hospital in Medan, the author found a problem, namely: "How do I get an optimal radiographic picture of the calcaneus bone with suspected spur formation?"

2. Cause of Problem

The causes of problems from examining the calcaneus os with suspected spur formation are [26]:

- a. The patient cannot cooperate or is uncooperative because of the pain caused by the spur, and can hinder the examination process.
- b. To obtain an optimal image, the patient can use immobilization tools such as sponges and ropes for examination in axial projection to reduce patient movement and make the patient comfortable.

3. Efforts Made to Overcome Problems [27]. The efforts made to overcome problems in examining the calcaneus os with suspected spur formation are:

a. Patient Aspect

Good cooperation between the patient and the radiographer helps the examination run smoothly.

b. Radiographic Aspects

To expedite the course of the examination, the radiographer must provide an explanation to the patient or patient's family about the examination procedure that will be carried out [28].

c. Aspects of Patient Comfort

Because the pain makes the patient uncomfortable, a pillow should be given under the patient's head.

d. Image Recording Aspects

When examining the calcaneus bone with suspected spur formation, the image is recorded using Computer Radiography (CR) because it is more efficient [29].

e. Exposure Aspect

To obtain optimal image results with good sharpness and detail, the area of the illumination field must be adjusted to the area of the object being photographed [30].

4. CONCLUSION

After conducting research on the examination of the calcaneus os with suspected spur formation, the author came to the following conclusions:

1. Good cooperation between the radiographer and the patient can make the examination smoother.
2. Patient comfort supports the implementation of a good examination.
3. In radiography of the calcaneus bone with suspected spur formation, the image recording process used is by using Computer Radiography (CR).

ACKNOWLEDGEMENTS

The author would like to thank for all the help and support provided until the article was completed and published.

REFERENCES

- [1] V. Torrecillas and J. D. Meier, "History and radiographic findings as predictors for esophageal coins versus button batteries," *Int. J. Pediatr. Otorhinolaryngol.*, vol. 137, no. 5, p. 110208, Oct. 2020, doi: 10.1016/j.ijporl.2020.110208.
- [2] V. Sharma, K. Kumar, V. Kalia, and P. Soni, "Evaluation of femoral neck-shaft angle in subHimalayan population of North West India using digital radiography and dry bone measurements," *J. Sci. Soc.*, vol. 45, no. 1, p. 3, 2018, doi: 10.4103/jss.JSS_34_17.
- [3] S. Lampridis, S. Mitsos, M. Hayward, D. Lawrence, and N. Panagiotopoulos, "The insidious presentation and challenging management of esophageal perforation following diagnostic and therapeutic interventions," *J. Thorac. Dis.*, vol. 12, no. 5, pp. 2724–2734, May 2020, doi: 10.21037/jtd-19-4096.
- [4] A. K. Prakash, S. G. Kotalwar, B. Datta, P. Chatterjee, S. Mittal, and A. Jaiswal, "To evaluate the inter and intraobserver agreement in the initial diagnosis by digital chest radiograph sent via whatsapp messenger," in *Imaging*, Sep. 2019, p. PA4820, doi: 10.1183/13993003.congress-2019.PA4820.
- [5] A. Patel, F. Schnoll-Sussman, and C. P. Gyawali, "Diagnostic Testing for Esophageal Motility Disorders: Barium Radiography, High-Resolution Manometry, and the Functional Lumen Imaging Probe (FLIP)," in *The AFS Textbook of Foregut Disease*, Cham: Springer International Publishing, 2023, pp. 269–278.
- [6] V. Sharma, K. Kumar, V. Kalia, and P. K. Soni, "Evaluation of femoral neck-shaft angle in subHimalayan population of North West India using digital radiography and dry bone measurements," *J. Sci. Soc.*, vol. 45, no. 1, pp. 3–7, 2018.
- [7] R. Whelan, A. Shaffer, and J. E. Dohar, "Button battery versus stacked coin ingestion: A conundrum for radiographic diagnosis," *Int. J. Pediatr. Otorhinolaryngol.*, vol. 126, p. 109627, Nov. 2019, doi: 10.1016/j.ijporl.2019.109627.
- [8] I. A. N. Liscyaningsih, M. Fa'ik, and V. V. Felleaningrum, "Difference in Radiograph Image Between Prints Directly on CR Modality with Print Through PACS," in *2022 'AISYIYAH International Conference on Health and Medical Sciences (A-HMS 2022)*, Atlantis Press, 2023, pp. 248–253.
- [9] M. J. Nelson *et al.*, "Comparison of endoscopy and radiographic imaging for detection of esophageal inflammation and remodeling in adults with eosinophilic esophagitis," *Gastrointest. Endosc.*, vol. 87, no. 4, pp. 962–968, Apr. 2018, doi: 10.1016/j.gie.2017.09.037.
- [10] G. Cutaia *et al.*, "Caustic ingestion: CT findings of esophageal injuries and thoracic complications," *Emerg. Radiol.*, vol. 28, no. 4, pp. 845–856, Aug. 2021, doi: 10.1007/s10140-021-01918-1.

- [11] D. A. PURWANINGSIH, "Analisis Spektrum Sinar-X Industri Mitech X-Ray Flaw Detector dan Uji Efektivitas Proteksi Radiasi Menggunakan Material Timbal." Universitas Jenderal Soedirman, 2022, [Online]. Available: <http://repository.unsoed.ac.id/id/eprint/18351>.
- [12] A. Peiro, N. Chegeni, A. Danyaei, M. Tahmasbi, and J. FatahiAsl, "Pelvis received dose measurement for trauma patients in multi-field radiographic examinations: A TLD dosimetry study," 2022.
- [13] Z. Farzanegan, M. Tahmasbi, M. Cheki, F. Yousefvand, and M. Rajabi, "Evaluating the principles of radiation protection in diagnostic radiologic examinations: collimation, exposure factors and use of protective equipment for the patients and their companions," *J. Med. Radiat. Sci.*, vol. 67, no. 2, pp. 119–127, Jun. 2020, doi: 10.1002/jmrs.384.
- [14] W. Elshami, M. M. Abuzaaid, and H. O. Tekin, "Effectiveness of breast and eye shielding during cervical spine radiography: an experimental study," *Risk Manag. Healthc. Policy*, pp. 697–704, 2020.
- [15] A. D. Stirling, M. C. Murphy, W. L. Murray, and J. G. Murray, "Patient's posteroanterior chest radiographs are routinely displayed at different sizes on PACS: Cause and prevalence," *Clin. Imaging*, vol. 90, pp. 59–62, Oct. 2022, doi: 10.1016/j.clinimag.2022.07.010.
- [16] P. S. Hajare, A. V. Jadhav, P. H. Patil, and S. S. Das, "A Cadaveric Study of Anatomical and Radiological Correlation of Mastoid Air Cells System in Relation to its Morphology," *Indian J. Otolaryngol. Head Neck Surg.*, vol. 75, no. S1, pp. 242–249, Apr. 2023, doi: 10.1007/s12070-022-03341-5.
- [17] M. Z. Adışen and M. Aydoğdu, "Comparison of mastoid air cell volume in patients with or without a pneumatized articular tubercle," *Imaging Sci. Dent.*, vol. 52, no. 1, p. 27, 2022, doi: 10.5624/isd.20210153.
- [18] N. M. Etedali, J. A. Reetz, and J. D. Foster, "Complications and clinical utility of ultrasonographically guided pyelocentesis and antegrade pyelography in cats and dogs: 49 cases (2007–2015)," *J. Am. Vet. Med. Assoc.*, vol. 254, no. 7, pp. 826–834, Apr. 2019, doi: 10.2460/javma.254.7.826.
- [19] C. Lemieux, C. Vachon, G. Beauchamp, and M. E. Dunn, "Minimal renal pelvis dilation in cats diagnosed with benign ureteral obstruction by antegrade pyelography: a retrospective study of 82 cases (2012–2018)," *J. Feline Med. Surg.*, vol. 23, no. 10, pp. 892–899, Oct. 2021, doi: 10.1177/1098612X20983980.
- [20] L. Meomartino, A. Greco, M. Di Giancamillo, A. Brunetti, and G. Gnudi, "Imaging techniques in Veterinary Medicine. Part I: Radiography and Ultrasonography," *Eur. J. Radiol. Open*, vol. 8, p. 100382, 2021, doi: 10.1016/j.ejro.2021.100382.
- [21] M. Lee *et al.*, "Role of buccal mucosa graft ureteroplasty in the surgical management of pyeloplasty failure," *Asian J. Urol.*, Nov. 2023, doi: 10.1016/j.ajur.2023.09.001.
- [22] T. Tanaka, T. Shindo, K. Hashimoto, K. Kobayashi, and N. Masumori, "Management of hydronephrosis after radical cystectomy and urinary diversion for bladder cancer: A single tertiary center experience," *Int. J. Urol.*, vol. 29, no. 9, pp. 1046–1053, 2022, doi: <https://doi.org/10.1111/iju.14970>.
- [23] E. G. Nordio, N. V. Tumanska, and T. M. Kichangina, "Radiological investigation of the urogenital system," 2018.
- [24] R. Tamura, R. Tomio, F. Mohammad, M. Toda, and K. Yoshida, "Analysis of various tracts of mastoid air cells related to CSF leak after the anterior transpetrosal approach," *J. Neurosurg.*, vol. 130, no. 2, pp. 360–367, Feb. 2019, doi: 10.3171/2017.9.JNS171622.
- [25] D. d'Ovidio, F. Pirrone, T. M. Donnelly, A. Greco, and L. Meomartino, "Ultrasound-guided percutaneous antegrade pyelography for suspected ureteral obstruction in 6 pet guinea pigs (*Cavia porcellus*)," *Vet. Q.*, vol. 40, no. 1, pp. 198–204, Jan. 2020, doi: 10.1080/01652176.2020.1803512.
- [26] F. P. Machado, J. E. F. Dornelles, S. Rausch, R. J. Oliveira, P. R. Portela, and A. L. S. Valente, "Osteology of the pelvic limb of nine-banded-armadillo, *Dasypus novemcinctus* Linnaeus, 1758 applied to radiographic interpretation," *Brazilian J. Dev.*, vol. 9, no. 05, pp. 14686–14709, 2023.
- [27] J. M. Elmore, W. H. Cerwinka, and A. J. Kirsch, "Assessment of renal obstructive disorders: ultrasound, nuclear medicine, and magnetic resonance imaging," in *The Kelalis--King--Belman Textbook of Clinical Pediatric Urology*, CRC Press, 2018, pp. 495–504.
- [28] C. Yuan *et al.*, "Ileal ureteral replacement for the management of ureteral avulsion during ureteroscopic lithotripsy: a case series," *BMC Surg.*, vol. 22, no. 1, pp. 1–8, 2022.
- [29] L. Munhoz, C. HIROSHI IIDA, R. Abdala Junior, R. Abdala, and E. S. Arita, "Mastoid Air Cell System: Hounsfield Density by Multislice Computed Tomography.," *J. Clin. Diagnostic Res.*, vol. 12, no. 4, 2018.
- [30] D. Rochmayanti *et al.*, "Image Improvement and Dose Reduction on Computed Tomography Mastoid Using Interactive Reconstruction," in *Journal of Big Data*, vol. 9, no. 1, SpringerOpen, 2023, pp. 103–116.