

Fat Emboli with Thrombocytopenia in A Patient Undergoing Operation for A 1/3 Medial Humerus Oblique Fracture

Son Ardianto¹, Devin Alexander², Budi Wahono³

¹Faculty of Medicine, Tarumanagara University, Jakarta, Indonesia

²General Practitioners at RAA Soewondo Regional Hospital, Pati, Indonesia

³Anesthesia Department RAA Soewondo Regional Hospital, Pati, Indonesia

Article Info

Article history:

Received February 07, 2024

Revised February 11, 2024

Accepted February 13, 2024

Corresponding Author:

Son Ardianto

Faculty of Medicine,

Tarumanagara University,

Jakarta

Email:

son.406212001@stu.untar.com

ABSTRACT

Fat embolism is a clinical syndrome characterized by the systemic spread of fat emboli which often occurs due to fractures in long bones. We report a 29 year old man with a diagnosis of a fracture of the medial third of the right humerus accompanied by thrombocytopenia which could be one of the clinical manifestations of pulmonary embolism. A 29 year old man came to the emergency room at RAA Soewondo Pati Regional Hospital with complaints of pain in his right hand 2 hours before entering the hospital. The patient felt pain after falling and slipping at home. Physical examination revealed tachycardia and tachypnea. Humeral x-ray revealed discontinuity in the medial 1/3 of the right humerus. The patient then underwent treatment for the fracture and the day after a routine blood test was carried out. Routine blood tests revealed thrombocytopenia. Fat embolism is a dangerous complication of long bone fractures. Often this fat embolism is not recognized until the patient shows symptoms in several systems, especially the respiratory system such as respiratory distress and neurological system disorders ranging from motor disorders to seizures. Apart from that, fat embolism can also disrupt the coagulation system so that thrombocytopenia can occur. In this patient there was tachypnea and thrombocytopenia which could be early symptoms of fat embolism. Fat embolism is a complication of long bone fractures that is rare but dangerous if not properly recognized. Immediate management of fractures and collaboration with anesthesiologists and internists are important to prevent fat embolism.

Keywords:

Fat embolism, Fracture, Respiratory Distress, Thrombocytopenia

This article is licensed under a [Creative Commons Attribution 4.0 International License](https://creativecommons.org/licenses/by-sa/4.0/)



1. INTRODUCTION

A humerus fracture is a discontinuity that occurs in the humerus bone. Humerus fractures account for 1-3% of all fractures that can occur in humans. There are 3 (three) parts where a fracture can occur in the humerus bone, namely the proximal part, the shaft and the distal part, where of these three fractures, the stem fracture is the most common fracture, accounting for 4-6% of all cases human fractures, especially in the young and elderly [1].

Humerus fractures can cause several complications, ranging from acute complications such as nerve injury, to rare complications such as fat embolism. Fat embolism is a clinical syndrome characterized by the systemic spread of fat emboli, where these emboli disrupt capillaries and affect microcirculation, causing a systemic inflammatory response [2]. This syndrome is most often experienced by patients with orthopedic trauma [3]. It is estimated that 67% of patients who experience orthopedic trauma have fat clots in their blood. Apart from pre-operatively, fat embolism can also occur intraoperatively during fracture management [4]. Fat embolism can cause blockage of blood vessels in various organs, including the central nervous and respiratory systems, which can cause seizures and respiratory distress [5]. One way to prevent fat embolism is good perioperative preparation and treatment. We report a 29-year-old man with a fracture of the medial 1/3 of the humerus who was suspected of having fat embolism after open reduction and internal fixation surgery [6].

METHODS

Case Illustrations

A 29 year old man came to the emergency room at RAA Soewondo Pati Regional Hospital with complaints of pain in his right hand since 2 hours before entering the hospital. Pain felt after falling due to slipping at home [7]. When falling, the patient is in a position supporting his right hand. Before the fall the patient did not feel dizzy, and did not consume alcoholic drinks or drugs. Other complaints were denied. The patient also had no history of any disease and was immediately rushed to the emergency room after falling [8]. The patient has a habit of smoking 1 pack per day and works mostly in a sitting position [9].

Physical examination of vital signs revealed tachycardia and tachypnea. Organ examination is within normal limits. Localized status shows deformity, sharp pain on palpation, crepitation (+), and limited range of motion of the cubital and humeral joints. X-ray examination of the right antebrachii revealed discontinuity in the medial 1/3 of the humerus with lateral angulation [10]. Chest x-ray and EKG examination were within normal limits [11].

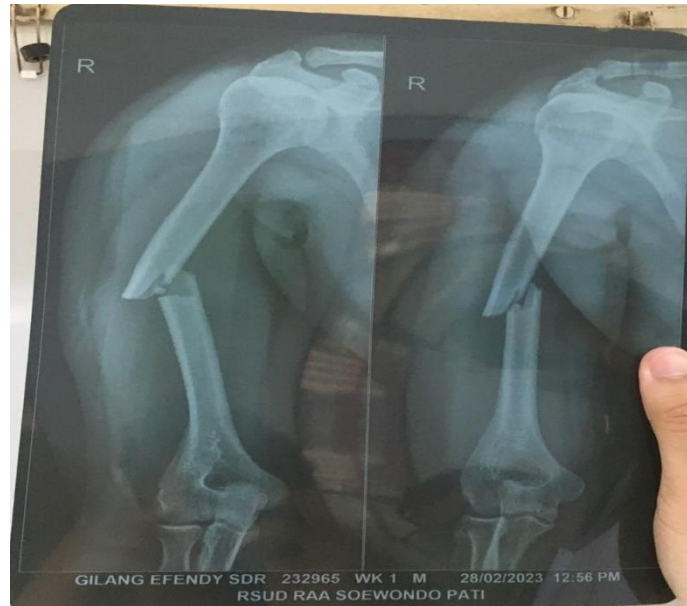


Figure 1. Humeral X-Ray Shows Discontinuity In The Medial 1/3 Of The Humeral Bone

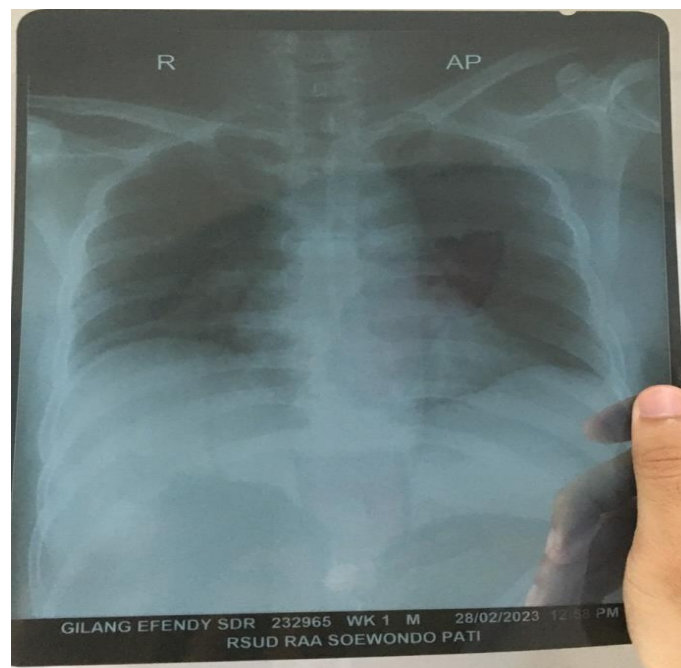


Figure 2. Patient's Thorax X-ray is found to be within normal limits

The patient was then diagnosed with a complete closed fracture of the medial 1/3 of the right humerus and thrombocytopenia et cause suspected fat embolism [12]. The patient received Ringer Lactate infusion therapy 20 tpm, ketorolac injection 2x1 ampoule, esomeprazole injection 1x1 ampoule and was planned to be repositioned via open reduction internal fixation (ORIF) [13]. After a pre-operative examination by the anesthesia department, the patient then underwent the ORIF installation procedure on the same day [14]. After the operation is complete, the patient is then followed up by asking about his complaints and carrying out routine blood tests. From the anamnesis, it was found that the patient still complained of pain in his hand and it was still difficult to move. Routine blood tests revealed thrombocytopenia [15]. After close monitoring, the patient was sent home on the 5th day of treatment because there were no other complaints in the patient [16].

2. RESULTS AND DISCUSSION

Fat embolism is a condition where there are fat particles in the microcirculation, and these fat particles can spread throughout the blood vessels that supply the body's organs, causing a collection of symptoms known as fat embolism syndrome (FES). There are 2 (two) body organs that are most often attacked, namely the respiratory system and the central nervous system, so that respiratory distress and acute changes in mental status can occur. Fat embolism is most often caused by orthopedic trauma with the most common causes being fractures of the long bones of the lower extremities, especially the femur, and less common causes being bone marrow transplant procedures, osteomyelitis, pancreatitis, alcoholic fatty liver and liposuction procedures [17]. The risk of FES which worsens orthopedic trauma is highest at the age of 10-40 years with the frequency of occurrence in men being greater than in women. 6,7 In this patient, the patient was 29 years old and male, and there was orthopedic trauma, namely a fracture of the humerus bone which could be the cause of fat embolism [18].

Although disease This long known, pathophysiology the occurrence of FES still occurs Not yet is known with Certain. There are 2 (two) theories Popular pathophysiology of FES, viz theory obstruction mechanic And injury biochemistry [19]. Theory obstruction mechanic state that cell existing fat in the marrow bone get access going to veins after trauma occurs. In his journey For until to this vein, cells fat that has pro- inflammatory effect And prothrombotic will trigger happen system coagulation, begins from aggregation platelets And formation fibrin threads, and Then stay in the circle arteries pulmonary [20]. Blockage arteries pulmonary This will cause happen bleeding and interstitial edema, alveolar disorders and narrowing vessels blood consequence lack of oxygen. The second theory, namely theory biochemical opinion that symptom clinical FES occurs Because circumstances inflammation [21]. Fat on marrow bone broken down by lipase enzymes and Then release sour fat free And glycerol which is poison [15]. Product poisonous this is what causes it organ dysfunction [21]. Manifestation clinical from fat embolism syndrome many kinds of depends from the organ system attacked, with multiple target organs are affected is system respiratory, system nerve center and system clumping blood. On in essence, manifestation clinical This happen consequence exists blockage And product poison like sour fat free And glycerol, so respiratory distress, encephalopathy, deficits occur neurological, petechiae, and disturbance other coagulation. On patient This obtained exists tachypnea with still saturation Good without exists disturbance neurological like decline awareness or disturbance sensory, but on inspection laboratory obtained exists thrombocytopenia, where exists tachypnea And thrombocytopenia can leads to fat embolism [22].

Do operation repair (repair) to be governance main For prevent occurrence of FES, with fixation internal can reduce occurrence of FES. Patient This direct done ORIF surgery after the diagnosis is established, so the possibility of FES can reduced in a way significant [23]. Besides that, management of fat embolism covers governance supportive And pharmacology [24]. Governance existing pharmacology Now Still Not yet proven can prevent the occurrence of FES, such as giving anticoagulant like heparin does proven can reduce possibility the occurrence of FES and even Now Already No recommended Again Because effect side the bleeding. Giving corticosteroids can given with base mechanism anti- inflammatory action, however results from other research still controversial. Although Still controversial, some clinician still give methylprednisolone as FES prophylaxis before done operation, with dose varies from 6-90 mg/ kgbb [25]. Governance supportive become the only one possible therapy done if FES symptoms already developing, which includes supplementation oxygen For repair oxygenation, ventilation when patient experiencing respiratory distress [26]. Shock can happen on FES and required fluid resuscitation [27]. On patient This No there is respiratory distress, shock or disturbance neurological so that No given resuscitation fluid or giving ventilation mechanic [28].

Governance from facet anesthesia covers oxygenation if respiratory distress occurs. Measurement saturation oxygen with tool oximetry pulse can detect exists hypoxemia which is not recognized. If Already happen decline saturation, then need given therapy oxygen And provision of ventilators is possible done as action prevention if saturate patient No increase with therapy oxygen previously [29]. No There is specific ventilator strategy For treat respiratory distress due to fat embolism [30].

3. CONCLUSION

Fat embolism is Wrong One rare complications found on patient fracture, but will fatal if No recognized in a way early. Governance pharmacology No can prevent the occurrence of FES and if FES is complete happens, just can

done therapy supportive just . Introduction early, treat quick from fracture, as well collaboration with anesthesia And disease in become key main in prevent occurrence of fat embolism.

REFERENCES

- [1] A. Kobryn, P. Nian, J. Baidya, T. L. Li, And A. V Maheshwari, “Intramedullary Nailing With And Without The Use Of Bone Cement For Impending And Pathologic Fractures Of The Humerus In Multiple Myeloma And Metastatic Disease,” *Cancers (Basel)*, Vol. 15, No. 14, P. 3601, Jul. 2023, Doi: 10.3390/Cancers15143601.
- [2] D. Z. You, “Studying Hypercoagulability In Hip Fracture Patients As Determined By Thrombelastography.” Cumming School Of Medicine, 2020.
- [3] B. E. Williams, A. A. Nair, P. James, B. Isaac, R. Gupta, And A. Ashok, “Fat Emboli—Related Diffuse Alveolar Haemorrhage (Fedah) An Acronym To Remember—Case Series,” *Respirol. Case Reports*, Vol. 11, No. 10, P. E01214, Oct. 2023, Doi: 10.1002/Rcr2.1214.
- [4] A. A. A. Wagealla, “Study Of Deep Vein Thrombosis In Fractured Lower Extremities Using Doppler Ultrasonography.” Sudan University Of Science And Technology, 2018.
- [5] C. M. Costelloe *Et Al.*, “Bone Metastases: Mechanisms Of The Metastatic Process, Imaging And Therapy,” *Semin. Ultrasound, Ct Mri*, Vol. 42, No. 2, Pp. 164–183, Apr. 2021, Doi: 10.1053/J.Sult.2020.08.016.
- [6] A. Kobryn, P. Nian, J. Baidya, T. L. Li, And A. V. Maheshwari, “Intramedullary Nailing With And Without The Use Of Bone Cement For Impending And Pathologic Fractures Of The Humerus In Multiple Myeloma And Metastatic Disease,” *Cancers (Basel)*, Vol. 15, No. 14, P. 3601, Jul. 2023, Doi: 10.3390/Cancers15143601.
- [7] A. Wilson, A. Hanandeh, A. A. Shamia, K. Louie, And B. Donaldson, “Effective Management Of Femur Fracture Using Damage Control Orthopedics Following Fat Embolism Syndrome,” *Cureus*, Vol. 12, No. 3, 2020.
- [8] A. Alsaghir, L. Alsaghir, J. Alsaif, And A. Mobeireek, “Successful Therapeutic Plasma Exchange For A Patient With Sickle Cell Disease And Fat Embolism Syndrome After A Failure Of A Response To Red Cell Exchange Transfusion,” *Transfusion*, Vol. 63, No. S1, Pp. S33–S36, Feb. 2023, Doi: 10.1111/Trf.17220.
- [9] D. L. Rothberg And C. A. Makarewich, “Fat Embolism And Fat Embolism Syndrome,” *J. Am. Acad. Orthop. Surg.*, Vol. 27, No. 8, Pp. E346–E355, Apr. 2019, Doi: 10.5435/Jaaos-D-17-00571.
- [10] D. A. Godoy, M. Di Napoli, And A. A. Rabinstein, “Cerebral Fat Embolism: Recognition, Complications, And Prognosis,” *Neurocrit. Care*, Vol. 29, No. 3, Pp. 358–365, Dec. 2018, Doi: 10.1007/S12028-017-0463-Y.
- [11] C. M. Milroy And J. L. Parai, “Fat Embolism, Fat Embolism Syndrome And The Autopsy,” *Acad. Forensic Pathol.*, Vol. 9, No. 3–4, Pp. 136–154, Sep. 2019, Doi: 10.1177/1925362119896351.
- [12] E. Caceres, A. E. V. Garces, And J. S. Vargas, “Cerebral Fat Embolism: Report Of Two Cases And Literature Review,” *Acta Colomb. Cuid. Intensivo*, Vol. 23, No. 3, Pp. 314–320, Jul. 2023, Doi: 10.1016/J.Acci.2023.04.004.
- [13] S. G. Morales-Vidal, “Neurologic Complications Of Fat Embolism Syndrome,” *Curr. Neurol. Neurosci. Rep.*, Vol. 19, No. 3, P. 14, Mar. 2019, Doi: 10.1007/S11910-019-0928-9.
- [14] M. Bortolotti *Et Al.*, “A Suspected Case Of Cerebral Fat Embolism Triggering A Drug-Resistant Status Epilepticus In A Hbs/B⁺-Thalassaemia Patient,” *Mediterr. J. Hematol. Infect. Dis.*, Vol. 14, No. 1, P. E2022019, Feb. 2022, Doi: 10.4084/Mjhid.2022.019.
- [15] Y. Olivera Arencibia *Et Al.*, “Fat Embolism And Nonconvulsive Status Epilepticus,” *Case Rep. Neurol. Med.*, Vol. 2018, 2018.
- [16] D. A. Tsitsikas, J. Bristowe, And J. Abukar, “Fat Embolism Syndrome In Sickle Cell Disease,” *J. Clin. Med.*, Vol. 9, No. 11, P. 3601, Nov. 2020, Doi: 10.3390/Jcm9113601.
- [17] D. D Ro euth *Et Al.*, “Fat Embolism Syndrome In A Patient With Sickle Cell Crisis Mimicking Thrombotic Thrombocytopenic Purpura,” *Chest*, Vol. 164, No. 4, Pp. A1549–A1550, 2023.
- [18] R. Gangaraju, J. May, P. MacLennan, V. V. B. Reddy, And M. B. Marques, “Differentiating Fat Embolism Syndrome Due To Bone Marrow Necrosis In Patients With Sickle Hemoglobinopathies From Thrombotic Thrombocytopenic Purpura (Ttp),” *Blood*, Vol. 132, No. Supplement 1, Pp. 1090–1090, Nov. 2018, Doi: 10.1182/Blood-2018-99-112621.
- [19] J. Shaw Huffman And C. Humston, “Fat Embolism Syndrome Revisited: A Case Report And Review Of Literature, With New Recommendations For The Anesthetized Patient.,” *Aana J.*, Vol. 88, No. 3, 2020.
- [20] L. Cárdenas-Camarena, H. Durán, J. A. Robles-Cervantes, And J. E. Bayter-Marin, “Critical Differences Between Microscopic (Mife) And Macroscopic (Mafe) Fat Embolism During Liposuction And Gluteal Lipoinjection,” *Plast. Reconstr. Surg.*, Vol. 141, No. 4, Pp. 880–890, Apr. 2018, Doi: 10.1097/Prs.00000000000004219.
- [21] F. D. V. M. Nogueira, G. V. B. F. Coelho, V. F. Da Silveira Junior, C. Z. N. De Andrade, C. M. C. Hetem, And J. A. Farina Junior, “Liposuction And Fat Embolism: A Literature Review,” *Rev. Bras. Cir. Plástica – Brazilian J. Plast. Surgery*, Vol. 30, No. 2, Pp. 291–294, 2015, Doi: 10.5935/2177-1235.2015rbcp0157.

- [22] Y. Meng *Et Al.*, “Nontraumatic Multiple-Organ Fat Embolism: An Autopsy Case And Review Of Literature,” *Am. J. Forensic Med. Pathol.*, Vol. 41, No. 2, Pp. 131–134, 2020, Doi: [Http://Creativecommons.Org/Licenses/By-Nc-Nd/4.0/](http://creativecommons.org/licenses/by-nc-nd/4.0/).
- [23] D. A. Tsitsikas *Et Al.*, “Pitfalls In Diagnosing Thrombotic Thrombocytopenic Purpura In Sickle Cell Disease,” *J. Clin. Med.*, Vol. 11, No. 22, P. 6676, Nov. 2022, Doi: 10.3390/Jcm11226676.
- [24] N. K. Keyal, M. Nakarmi, A. Bhujel, And S. K. Yadav, “Human Albumin And N-Acetylcysteine For Treatment Of Fat Embolism: A Case Report,” *J. Nepal Med. Assoc.*, Vol. 57, No. 218, P. 263, Aug. 2019, Doi: 10.31729/Jnma.4478.
- [25] M. Alpert *Et Al.*, “Fat Embolism Syndrome In Blunt Trauma Patients With Extremity Fractures,” *J. Orthop.*, Vol. 21, Pp. 475–480, Sep. 2020, Doi: 10.1016/J.Jor.2020.08.040.
- [26] T. Suda *Et Al.*, “Fat Embolism Syndrome After Humerus And Pelvis Fracture Complicated By Acute Kidney Injury Requiring Blood Purification: A Case Report And Literature Review,” *Ren. Replace. Ther.*, Vol. 9, No. 1, P. 51, Oct. 2023, Doi: 10.1186/S41100-023-00504-0.
- [27] A. K. Kamboj, P. Hoversten, And C. L. Leggett, “Upper Gastrointestinal Bleeding: Etiologies And Management,” *Mayo Clin. Proc.*, Vol. 94, No. 4, Pp. 697–703, Apr. 2019, Doi: 10.1016/J.Mayocp.2019.01.022.
- [28] R. Kammeyer, R. Devnani, And R. Mehta, “Cerebral Fat Embolism Syndrome Mimicking Thrombotic Thrombocytopenic Purpura In A Patient With Hemoglobin Sc Disease,” *Am. J. Hematol.*, Vol. 91, No. 5, Pp. 539–542, May 2016, Doi: 10.1002/Ajh.24286.
- [29] Z. He *Et Al.*, “Single-Case Metanalysis Of Fat Embolism Syndrome,” *Int. J. Cardiol.*, Vol. 345, Pp. 111–117, Dec. 2021, Doi: 10.1016/J.Ijcard.2021.10.151.
- [30] R. Chaturvedi, A. Williams, N. Farid, T. Retson, And E. Smitaman, “Posttraumatic Subarachnoid Fat Embolism: Case Presentation And Literature Review,” *Clin. Imaging*, Vol. 68, Pp. 121–123, Dec. 2020, Doi: 10.1016/J.Clinimag.2020.06.035.